

White Paper on Functional Blepharoplasty, Blepharoptosis, and Brow Ptosis Repair American Society of Ophthalmic Plastic and Reconstructive Surgery (ASOPRS)

Preface

The American Society of Ophthalmic Plastic and Reconstructive Surgery (ASOPRS) is the nation's oldest and largest specialty society devoted to the treatment and surgery of eyelid, facial, lacrimal and orbital disorders. As of 2014, the Society has over 700 members who are Board Certified in Ophthalmology and undergo extensive fellowship training in the specialty of Oculofacial Plastic Surgery, a subspecialty of Ophthalmology. Membership is limited to physicians who have completed specialty training, passed rigorous testing requirements and completed a scholarly thesis. Priorities of the Society include continuing education of members, accreditation and oversight of fellowship training, and advocacy for patients.

Background

The number of Medicare claims for blepharoplasty has significantly increased over the last decade according to data released by the Department of Health and Human Services. Physicians and patients are faced with a dilemma when the coverage criteria for medical procedures are inconsistent and ambiguous. Patients need to know what constitutes medical necessity, and physicians need to know what documentation is required to justify their decision to proceed with surgery. Third party payors are concerned that coverage criteria sufficiently encompass functional problems while also addressing potential overutilization.

While blepharoplasty may be performed in some individuals for purely “cosmetic” reasons, others may have loss of their superior field of vision due to upper eyelid malposition (blepharoptosis and/or dermatochalasis) or eyebrow ptosis causing significant visual impairment. Quality of life studies support the association between superior visual field loss and difficulty with driving, reading, computer use, as well as other activities of daily living.^{1,2,3} Specifically, in the elderly, increasing loss of the superior visual field is associated with increasing risk of sustaining a fall.⁴

Unfortunately, third-party payors disagree as to what objective findings best demonstrate functional impairment of vision, making it difficult for physicians to determine which cases satisfy a specific payor’s criteria. In addition, governmental agencies recognize the need for standardized criteria and have recommended improvement in consistency of local coverage determinations (LCDs).⁵ It is the medical profession’s responsibility to establish such criteria that are obvious, objective, repeatable, evidence-based, testable and easily documented. It is the payor’s responsibility to implement these clearly defined criteria, and reimburse for services that meet the defined criteria. As technology advances, physicians will be better able to objectively assess functional deficits and expected improvement from eyebrow and eyelid surgery. The Society will make periodic assessments and revise this document as necessary.

This white paper serves to establish uniform objective, evidence-based criteria as the basis for functional upper eyelid blepharoplasty, blepharoptosis repair, and brow ptosis repair. Evidence-based criteria will be equally useful to patients, physicians and third-party payors and should legitimately balance the interests of all three parties. This paper addresses surgical indications predominantly due to involuntional causes for dermatochalasis, upper eyelid ptosis and brow ptosis. Evidence based criteria are necessary for involuntional changes because such changes both occur gradually over time and may cause overlapping cosmetic concerns. Therefore, involuntional changes must be clearly measured and defined for proper utilization and coverage. This paper does not address other indications for eyelid and eyebrow surgery secondary to medical conditions such as thyroid eye disease, cranial nerve palsy, periocular dermatitis, or changes related to the anophthalmic socket. However, when eyelid or eyebrow disorders occur as a direct result of an underlying pathologic disease process or trauma, we recommend that they should be considered functional rather than cosmetic and covered by third party carriers as such.

In instances in which upper eyelid blepharoplasty, blepharoptosis repair, or brow ptosis repair are performed for the primary purpose of improving an individual's appearance, they should be considered cosmetic and clearly excluded from consideration for third party payment. Furthermore, cosmetic eyelid surgery, primarily intended to improve aesthetic appearance and not visual function, is an arrangement personally and financially between an individual and surgeon and should not be covered or governed by third parties.

Upper eyelid blepharoplasty

Functional upper eyelid blepharoplasty is a surgical procedure performed to remove redundant upper eyelid skin in patients with obstructive dermatochalasis. An upper eyelid blepharoplasty is considered functional when the redundant tissue overhangs the upper eyelid to the point it produces significant visual field impairment in primary or down (reading) gaze. Such impairment may include difficulty with reading, ambulation, driving, using a computer, or working safely. Excess upper eyelid skin can rest on and depress the lashes obstructing vision (Figure 1). Dermatochalasis can produce "pseudo-ptosis," in which the upper eyelid skin falls over the upper eyelid margin giving the appearance of a "droopy" eyelid (see Upper Eyelid Ptosis Repair below). When severe, dermatochalasis results in the same functional visual impairment seen with true blepharoptosis even though the MRD may be greater than 2 mm (see below) when the excess skin is manually elevated.

Upper eyelid blepharoptosis repair

Blepharoptosis (ptosis) repair is a surgical procedure performed to elevate the upper eyelid margin in patients with congenital or acquired ptosis and can be accomplished by procedures such as external levator resection or advancement, posterior approach Müller's muscle and conjunctival resection, or frontalis suspension. Ptosis repair should be considered functional when the degree of ptosis is sufficiently severe to impair vision as described above for upper eyelid blepharoplasty.

Ptosis repair is a separate and distinct procedure from upper eyelid blepharoplasty surgery. Certain patients have visual field obstruction from the combined effects of both eyelid ptosis and excessive overhanging upper eyelid skin. Simultaneous or sequential upper eyelid blepharoplasty and ptosis repair may be required to provide sufficient functional improvement to correct both problems in these patients. An objective method of documenting the degree of ptosis is measuring the distance between the eyelid margin and the corneal light reflex (MRD, Margin to Reflex Distance). An MRD of 2 mm or less indicates a functionally low position of the upper eyelid (Figure 2) and has been shown in multiple studies to correlate well with a functional degree of superior visual field loss.⁶⁻¹¹ Monocular patients and patients with advanced visual field loss from other conditions (e.g., glaucoma) may experience functionally significant impairment with any degree of compromise of the eyelid aperture. Congenital ptosis can be noted at any age, and may affect visual development.

Brow ptosis repair

Brow ptosis (Figure 3) can exacerbate upper eyelid dermatochalasis and pseudoptosis by increasing upper eyelid redundant tissue. The normal eyebrow position rests at or above the superior orbital rim. Brow ptosis exists when the brow descends below the superior orbital rim. A brow lift is a surgical procedure to reposition a ptotic brow into a normal anatomic position. This can be performed along the brow itself, in the mid-forehead or with a coronal approach (CPT 67900). Forehead rhytidectomy (CPT 15824) is a cosmetic procedure performed to hide the scars of a forehead and/or brow lift, and includes the endoscopic approach. In some instances, both brow ptosis repair and blepharoplasty and/or lid ptosis repair may be required to adequately correct functional superior visual field loss.

Determination of Functional Visual Obstruction

A detailed history of the patient's complaint as to how the upper eyelid position, eyelid skin or brow descent affects the everyday functioning or quality of life should be obtained. The complaints may vary based on a variety of factors such as age, general medical condition, mental capacity, visual acuity, occupation of the patient, and the types of leisure or recreational activities enjoyed by the patient. Many common complaints relating to visual field loss include problems reading, driving, watching TV or using a computer. Patients might describe the need to manually elevate their eyelid to see and also might experience a brow ache or headache from constant brow elevation, adopt a compensatory chin elevation, or bump their head on overhead objects. Patients with ptosis or dermatochalasis may also complain of seeing their own lashes or feeling them irritating the cornea. Children with ptosis may not have complaints concerning visual function.

The physical exam should objectively document findings related to the patient's complaints. Measurements of visual acuity, MRD, description of the brow position and degree of excess skin, eyelid skin fold, and any abnormal lash position should be documented. Any recruitment of the frontalis muscle (forehead) elevating the droopy eyelid and excess eyelid skin fold to improve central or peripheral vision, and any chin up position should be noted. With the excess eyelid skin manually elevated, any true ptosis (i.e. abnormal MRD) should

be recorded. Residual visually significant excess eyelid skin or upper eyelid ptosis that is present after the brow is manually elevated to a normal position should be documented.

When visual field testing is performed, the forehead muscles must be completely relaxed, with the patient's eyelids and brows in their baseline resting position. The testing is repeated with the excess eyelid skin, ptotic eyelids, and/or ptotic brows elevated to normal anatomic position, thereby assessing superior or peripheral visual field loss due to eyelid skin or margin, or brow position. Unobstructed, the superior field normally measures approximately 45 to 50 degrees.¹² An MRD of 2 mm corresponds to a superior visual field impairment of 12-15 degrees.¹² Thus, a baseline superior visual field of 30-35 degrees corresponds to an MRD of 2mm. A superior visual field of 30 degrees or less that improves with eyelid and brow elevation corresponds to a functional superior visual field loss.

Good quality frontal photographs are the best objective way to document the patient's eyelid positions. The frontal plane of the face should be perpendicular to the camera with the patient looking straight ahead. The brows should be completely at rest so as to not give a falsely elevated eyelid position. Photographs should not be taken if the pupils have been pharmacologically dilated as this may give a falsely high eyelid position due to stimulation of Müller's muscle. Oblique or lateral photographs can be helpful in further demonstrating overhanging dermatochalasis, as well as lash ptosis due to mechanical displacement by the overhanging skin fold.

Some patients with involutional ptosis may only exhibit symptomatic visual field impairment in down-gaze.¹³⁻¹⁸ These patients often complain of difficulty walking while looking down, or the inability to read or work in the down-gaze position for long periods of time resulting in brow ache, fatigue, or having to manually elevate their eyelids.¹⁸ In cases in which the degree of ptosis in primary gaze does not initially meet inclusion criteria for functional ptosis surgery, but the patient complains of difficulty reading or completing other close work when looking down, the MRD should be measured and photographs taken in down-gaze. If the MRD in down-gaze measures 2 mm or less, functional ptosis surgery should be considered in order to improve visual function in these patients.

In a case of unilateral or asymmetric blepharoptosis, the less affected eyelid may maintain a normal or only slight depressed position due to its excessive stimulation by the levator subnucleus in the midbrain, which is responsible for innervating both eye lids simultaneously (Hering's law). If this is not detected prior to unilateral surgery, postoperative ptosis of the opposite eyelid may occur with new ptosis symptoms affecting the patient on the opposite side.¹⁹⁻²⁴ To rule out a Hering's law dependence, the more affected eye is either covered, or is elevated manually (Figure 4) or pharmacologically with the installation of phenylephrine drops. If the opposite normal or less affected eyelid becomes significantly more ptotic with an MRD of 2 mm or less, then bilateral ptosis surgery should be considered.²⁵

Recommended coverage indications

1. Upper eyelid blepharoplasty (CPT 15823) should be considered medically necessary

when documentation demonstrates:

- A. The patient's complaint of interference with daily visual tasks or visual field-related activities, and
 - B. Visual obstruction due to excessive overhanging skin resting on or depressing the lashes or eyelid margin. Visual obstruction is defined by peripheral visual field testing consistent with the recommended documentation requirement (see below).
2. Upper eyelid ptosis report (CPT 67901, 67902, 67903, 67904, 67906, 67908) should be considered medically necessary when documentation demonstrates:
- A. The patient's complaint of interference with vision or visual field-related activities, and
 - B. A margin to reflex distance (MRD) less than or equal to 2 mm in primary or downgaze.
 - C. Visual obstruction due to ptotic upper eyelid. Visual obstruction is defined by peripheral visual field testing consistent with the recommended documentation requirement (see below).
 - D. The position of one upper eyelid, which initially appears not to meet criteria but becomes more ptotic with an MRD of 2 mm or less when the other, more ptotic eyelid is elevated (i.e. Hering's Law) (Figure 4).
3. Repair of brow ptosis (CPT 67900) should be considered medically necessary when documentation demonstrates:
- A. Brow ptosis to the extent it contributes to skin fold overlap and/or blepharoptosis meeting the criteria outlined above for upper eyelid blepharoplasty and/or ptosis surgery.

Recommended documentation requirements

1. Clinical notes documenting patient complaints of visual impairment secondary to abnormal eyelid or brow position resulting in limitation of daily activities such as reading, driving, and difficulty seeing objects approaching from the periphery, or redundant upper eyelid skin resulting in looking through the eyelashes or seeing the upper eyelid skin.
2. Clinical notes documenting an MRD of 2 mm or less for blepharoptosis repair.
3. Peripheral visual field testing performed with the eyelid and brow in the resting position that documents a baseline superior visual field of 30 degrees or less from fixation and improvement of at least 12 degrees over baseline with eyelid and brow elevation. Both manual, including Goldmann and tangent screen (Figure 5), and automated fields (Figure 6) are acceptable. The measurement of a patient's superior visual field is defined as the lowest point seen at the vertical meridian. Visual fields are not required for children or other patients physically unable to perform visual field testing.

4. Photographs documenting the above including at least a good quality frontal upper face photograph, with the gaze in primary position clearly showing the corneal light reflex (Figure 7) unless the ptotic tissue is so severe as to obscure the light reflex thus demonstrating severe ptosis and/or dermatochalasis.
5. Oblique or lateral photographs if helpful in further demonstrating overhanging excess skin as well as lash ptosis due to mechanical displacement by the overhanging skin fold (Figure 8).
6. Frontal photograph with the patient looking in down-gaze documenting those cases in which the ptosis is worse in the down-gaze position.
7. Photograph with the brows elevated or taped up to a normal position to document the effect of brow ptosis when both eyelid ptosis repair and brow ptosis repair are planned (Figure 9).

References

1. Battu VK, Meyer DR, Wobig JL. Improvement in subjective visual function and quality of life outcome measures after blepharoptosis surgery. *Am J Ophthalmol* 1996;121(6):677-86.
2. Federici TJ, Meyer DR, Lininger LL. Correlation of the vision -related functional impairment associated with blepharoptosis and the impact of blepharoptosis surgery. *Ophthalmology* 1999;106(9):1705-12.
3. McKean-Cowdin R, Varma R, Wu J, et al. Severity of visual field loss and health-related quality of life. *Am J Ophthalmol* 2007;143(6):1013-23.
4. Freeman EE, Muñoz B, Rubin G, West SK. Visual field loss increases the risk of falls in older adults: the Salisbury Eye Evaluation. *Invest Ophthalmol Vis Sci* 07;48(10):4445-50.
5. Levinson DR. Local Coverage Determinations Create Inconsistency in Medicare Coverage. Inspector General Report, OEI-01-11-00500, January 2014.
6. Cahill KV, Burns JA, Weber PA. The effect of blepharoptosis on the field of vision. *Ophthal Plast Reconstr Surg* 1987;3(3):121-5.
7. Meyer DR, Linberg JV, Powell SR, Odom JV. Quantitating the superior visual field loss associated with ptosis. *Arch Ophthalmol* 1989;107(6):840-3.
8. Small RG, Sabates NR, Burrows D. The measurement and definition of ptosis. *Ophthal Plast Reconstr Surg* 1989;5(3):171-5.
9. Meyer DR, Stern JH, Jarvis JM, Lininger LL. Evaluating the visual field effects of blepharoptosis using automated static perimetry. *Ophthalmology* 1993;100(5):651-9.
10. Boboridis K, Assi A, Indar A, et al. Repeatability and reproducibility of upper eyelid measurements. *Br J Ophthalmol* 2001;85(1):99-101.
11. Hacker HD, Hollsten DA. Investigation of automated perimetry in the evaluation of patients for upper lid blepharoplasty. *Ophthal Plast Reconstr Surg* 1992;8(4):250-5.
12. Cahill KV, Bradley EA, Meyer DR, Custer PL, Holck DE, Marcet MM, Mawn LA. Functional Indications for Upper Eyelid Ptosis and Blepharoplasty Surgery. A Report by the American Academy of Ophthalmology. *Ophthalmology*, 2011; 118:2510-2517.
13. Waller RR, McCord CD Jr, Tanenbaum M. Evaluation and management of the ptosis patient. In: McCord CD Jr, Tanenbaum M, eds. *Oculoplastic Surgery*, 2nd ed. New York, NY: Raven Press, 1987:325-76.
14. Dryden RM, Kahanic DA. Worsening of blepharoptosis in downgaze. *Ophthal Plast Reconstr Surg* 1992;8(2):126-9.

15. Patipa M. Visual field loss in primary gaze and reading gaze due to acquired blepharoptosis and visual field improvement following ptosis surgery. *Arch Ophthalmol* 1992;110(1):63-7.
16. Wojno TH. Downgaze ptosis. *Ophthal Plast Reconstr Surg* 1993;9(2):83-9.
17. Meyer DR, Rheeman CH. Downgaze eyelid position in patients with blepharoptosis. *Ophthalmology* 1995;102(10):1517-23.
18. Olson JJ, Putterman A. Loss of vertical palpebral fissure height in downgaze in acquired blepharoptosis. *Arch Ophthalmol* 1995;113(10):1293-7.
19. Dresner MS. Ptosis and Hering's law. *Neurology* 1988;38(10):1661-2.
20. Gay AJ, Salmon MC, Windsor CE. Hering's law, the levators, and their relationship in disease states. *Arch Ophthalmol* 1967;77(2):157-60.
21. Mehta HK. The contralateral upper eyelid in ptosis: some observations pertinent to ptosis corrective surgery. *Br J Ophthalmol* 1979;63(2):20-4.
22. Bodian M. Lid droop following contralateral ptosis repair. *Arch Ophthalmol* 1982;100(7):1122-4.
23. McCulley TJ, Kersten RC, Kulwin DR, Feuer WJ. Outcome and influencing factors of external levator palpebrae superioris aponeurosis advancement for blepharoptosis. *Ophthal Plast Reconstr Surg* 2003;19(5):388-93.
24. Cetinkaya A, Kersten RC. Surgical outcomes in patients with bilateral ptosis and Hering's dependence. *Ophthalmology* 2012;119(2):376-81.
25. Zoumalan CI, Lisman RD. Evaluation and management of unilateral ptosis and avoiding contralateral ptosis. *Aesthet Surg J* 2010;30(3):320-8.

APPROVED

ASOPRS Executive Committee Final Draft, November 24, 2014

ASOPRS Membership Vote, December 5, 2014

ASOPRS Executive Committee Final Version, January 15, 2015

FIGURES

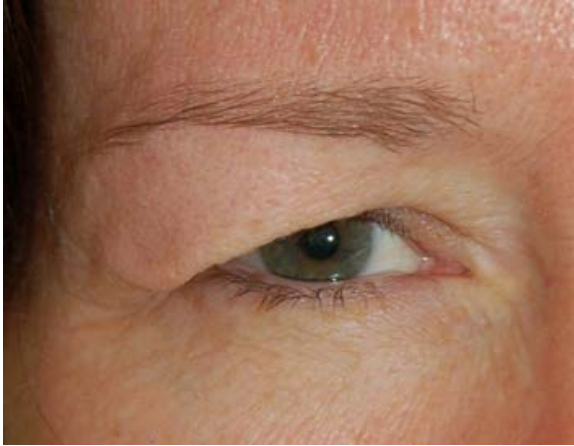

Figure 1. Visually significant upper eyelid dermatochalasis with excess skin fold draped over and depressing the eyelashes.

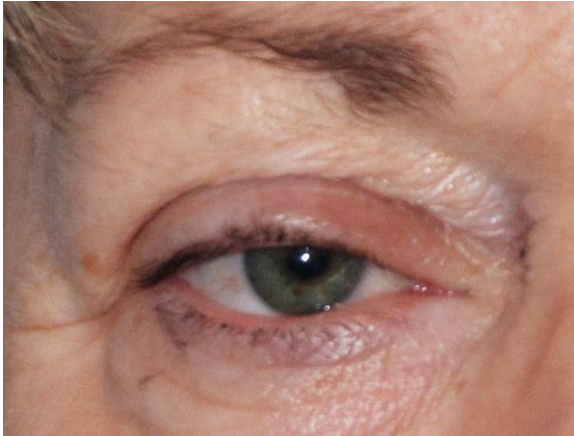

Figure 2. Upper eyelid ptosis with a margin to reflex distance (MRD) < 2mm.

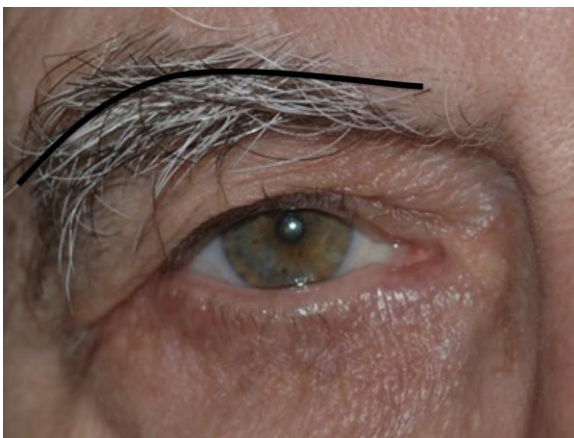
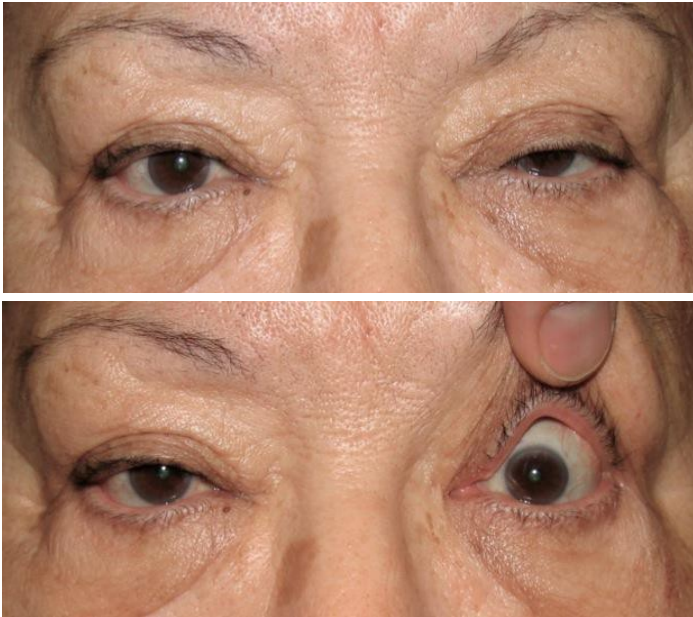
Figure 3. Brow ptosis. Note the proximity of the eyebrow hairs and the upper eyelid lashes. Brow rests below position of superior orbital rim (black line).



Figures 4A and 4B. Hering's Law – Note the ptosis of the right upper eyelid that develops when the left upper eyelid is manually elevated.

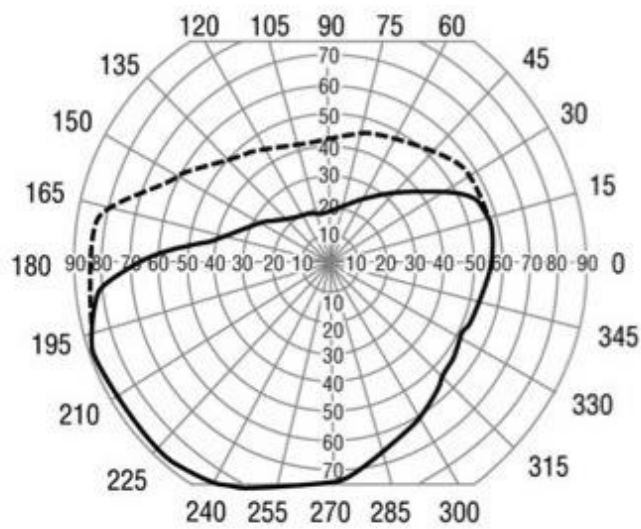


Figure 5. Goldmann (manual kinetic) ptosis field. The solid line is with the lid at resting position and the dotted line with the lid elevated and taped. The baseline superior field is 20 degrees and taping predicts a potential improvement of an additional 22 degrees.

CENTRAL REFERENCE: 32 DB
PERIPHERAL REFERENCE: 32 DB

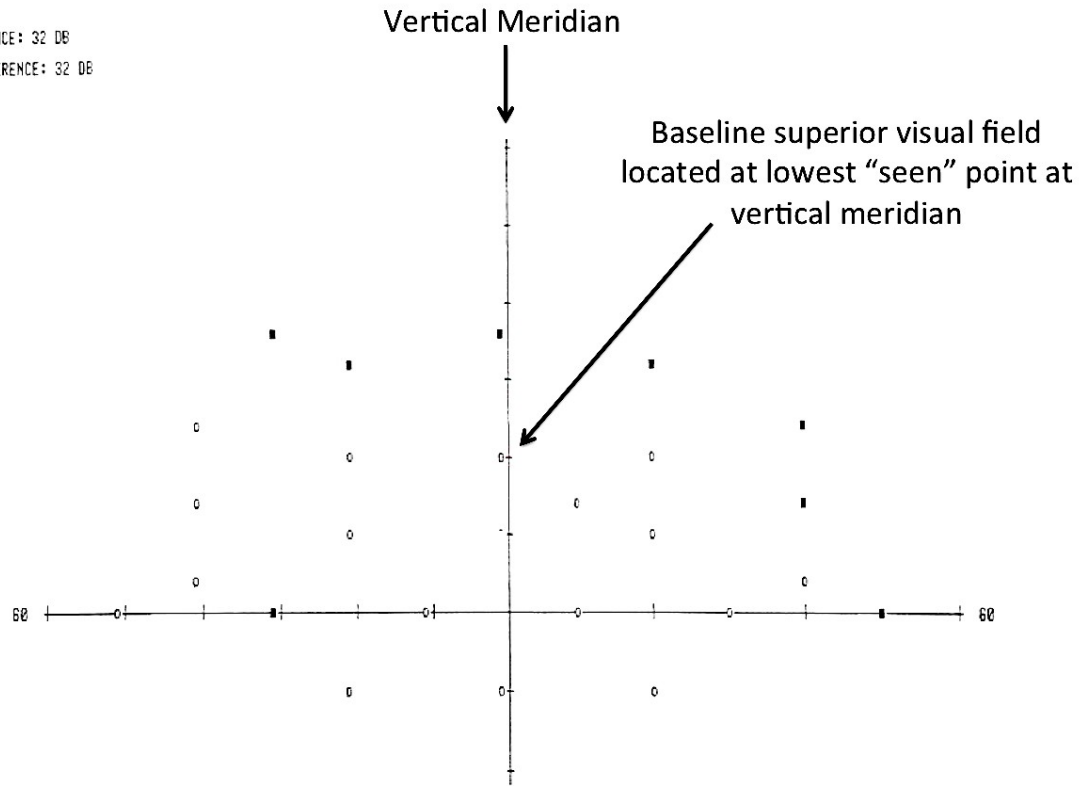


Figure 6. Automated visual field. When interpreting automated lid fields, the baseline superior visual field is defined as the lowest “seen” point on the vertical meridian (arrow). For this patient, the baseline superior visual field is 20 degrees (hash marks located at 10 degree intervals). In automated fields in which there are no midline points, the two lowest “seen” points straddling the vertical meridian are averaged and used as the baseline.

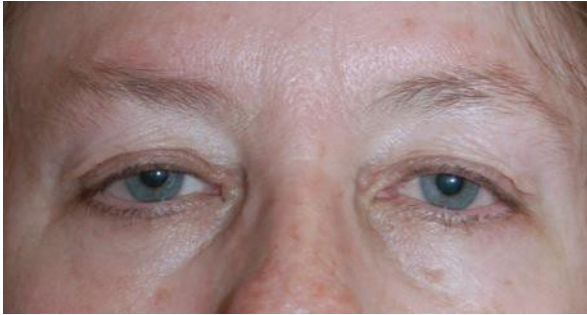

Figure 7. Frontal photograph with eyes in primary gaze demonstrating a clear corneal light reflex, MRD < 2 mm.

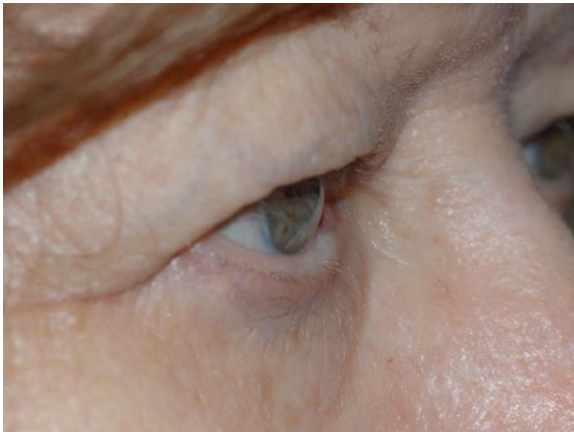

Figure 8. Oblique photograph demonstrating the excess upper eyelid skin resting on and depressing the eyelashes towards the cornea.

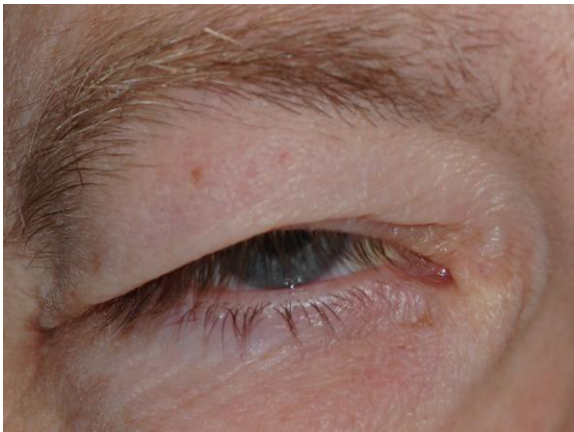

Figure 9A. Patient with functional brow ptosis and eyelid ptosis both affecting vision. .

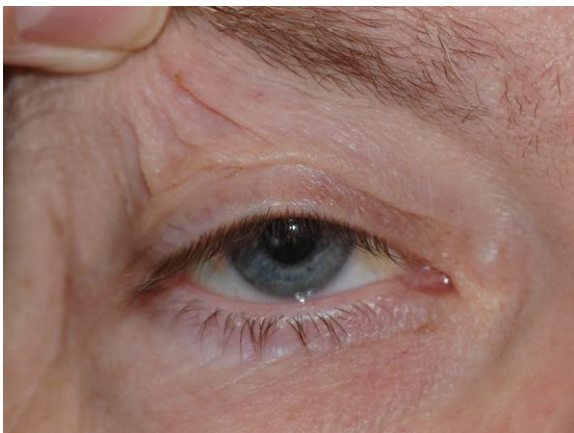

Figure 9B. With manual lifting of the eyebrow alone, the eyelid ptosis remains still causing visual obstruction. This example demonstrates the need for both brow ptosis and eyelid ptosis repair to restore normal visual function.